

# Apicotomy: Surgical management of maxillary dilacerated or ankylosed canines

Eustáquio A. Araújo,<sup>a</sup> Cristiana V. Araújo,<sup>b</sup> and Orlando M. Tanaka<sup>c</sup>

St Louis, Mo, Jacksonville, Fla, and Curitiba, Brazil

This clinical article reports a technique, apicotomy, for managing dilacerated or ankylosed canines. The records of 3 patients successfully treated with apicotomy are presented. Orthodontists observe clinically significant incidences of impacted maxillary canines in their daily practices. Several procedures have been described to bring an ankylosed, impacted tooth into occlusion. Luxation is the most widely used solution, but there are risks involved with that approach, and the success rate is low. Surgical repositioning has also been used, but morbidity is high, and the aggressiveness of the procedure might also contraindicate it. Ankylosis might be related to the anatomic position of the canine's root apex and its adjacent anatomic structures. Apicotomy is a guided fracture of a canine root apex, followed by its orthodontic traction. It is a conservative surgical alternative for treating impacted canines with dilacerations or apical root ankylosis. (*Am J Orthod Dentofacial Orthop* 2013;144:909-15)

Excluding the third molars, the maxillary canines are the most commonly impacted permanent teeth,<sup>1-3</sup> with impaction occurring more frequently in female patients than in males with a proportion of 2.5:1.<sup>4</sup> The theories of canine impaction include the distance they must travel to reach the occlusion, arch-length discrepancy, alveolar bone condensation, root dilaceration, and any form of ankylosis. The crown of impacted canines can be located labially or palatally but is most often palatal.<sup>5</sup> Asians have a significant number of labial impactions.

Occasionally, while attempting to bring an impacted tooth into proper occlusion, a clinician can be confronted with no response, and the first sign of ankylosis is frequently the intrusion of adjacent teeth. Dentoalveolar ankylosis is an anomaly of eruption that involves anatomic fusion of the alveolar bone with the cementum or dentin.<sup>6-8</sup>

Five treatment options for impacted maxillary canines are commonly considered: long-term monitoring,

interceptive removal of the deciduous canine to aid in the eruption of the permanent successor, surgical removal of the impacted canine, surgical exposure with orthodontic traction and alignment, and autotransplantation of the impacted canine.<sup>9</sup> It has been suggested that the treatment time for a malocclusion with an impacted canine might be longer than a similar malocclusion in which all teeth have erupted.<sup>10-12</sup> Much depends upon the tooth's position, eruption pattern, and stage of root formation.

Based on an investigation of impacted teeth, Puricelli<sup>13,14</sup> observed that the ankylosis might be related to the anatomic position of the canine's root apex and its adjacent anatomic structures. Puricelli has developed and described a surgical technique called *apicotomy*, a conservative intervention for impacted canines with dilacerations or apical root ankylosis. The diagnosis of apical root ankylosis is generally related to the position of the canine apex with the anatomic structure known as the inverted Y of Ennis. This structure is defined as the region where the cortices of the nasal cavity and the maxillary sinus meet.

The purpose of this article is to describe the technique and illustrate it with the records of 3 patients to demonstrate the retrieval of dilacerated or ankylosed maxillary canines.

## PROCEDURE

An apicotomy is a guided fracture of a canine root apex performed with a small chisel followed by orthodontic traction of the canine crown. The canine apex is surgically exposed, and a groove is made on the root

<sup>a</sup>Professor and clinic director, Graduate Orthodontic Program, Center for Advanced Dental Education, Saint Louis University, St Louis, Mo.

<sup>b</sup>Director of Fellowship in Orthodontics and Clinical Research, School of Orthodontics, Jacksonville University, Jacksonville, Fla.

<sup>c</sup>Professor, Graduate Dentistry Program in Orthodontics, Pontifícia Universidade Católica do Paraná, School of Health and Biosciences, Curitiba, Brazil; postdoctoral fellow, Center for Advanced Dental Education at Saint Louis University, St Louis, Mo.

All authors have completed and submitted the ICMJE Form for Disclosure of Potential Conflicts of Interest, and none were reported.

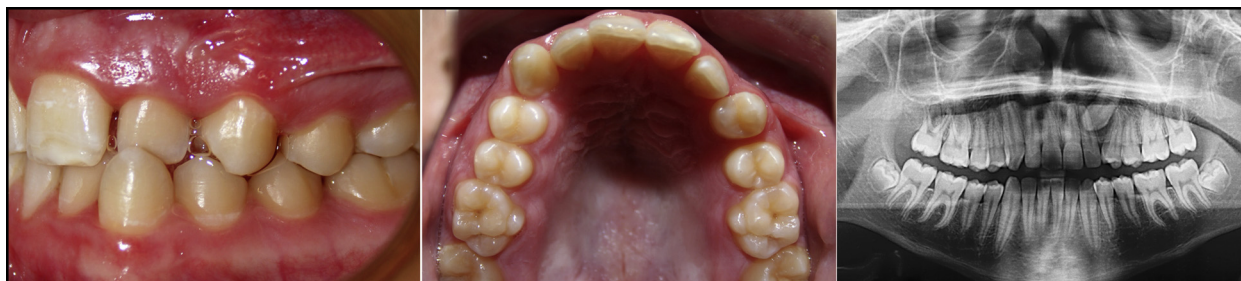Address correspondence to: Eustáquio A. Araújo, 3320 Rutger St, St Louis, MO 63104; e-mail, [araujoa@slu.edu](mailto:araujoa@slu.edu).

Submitted, July 2012; revised and accepted, January 2013.

0889-5406/\$36.00

Copyright © 2013 by the American Association of Orthodontists.

<http://dx.doi.org/10.1016/j.ajodo.2013.01.023>



**Fig 1.** Patient 1 had a Class I malocclusion with inadequate space for the impacted maxillary left canine.

with a small round dental bur, defining the place where the chisel should be placed for fracturing the root apex. The procedure has been successfully tested. Puricelli's data<sup>13,14</sup> showed that in 29 patients who had the procedure, 26 procedures were successful and 3 failed. In cases of failure, the canine must be extracted and another solution used.

A week after surgery, orthodontic traction should be applied with a force of approximately 100 g. A vertical direction of pull is preferred but not always possible. Ballista loops on round stainless steel 0.018-in wires have been shown to be effective. As the case progresses, the force can be slightly increased. The force should be monitored every 2 weeks because long periods without activation can lead to new ankylosis. Radiographic examinations are recommended at the start and again at 2 and 4 weeks. It is important to observe that the root tip is fractured and left in place to increase the chances of the tooth's remaining vital. Pulp tests should be performed after 3 months; in a significant number of patients, the tooth remains vital. Figures 1 through 11 illustrate the timing and the success of the apicotomies in 3 patients.

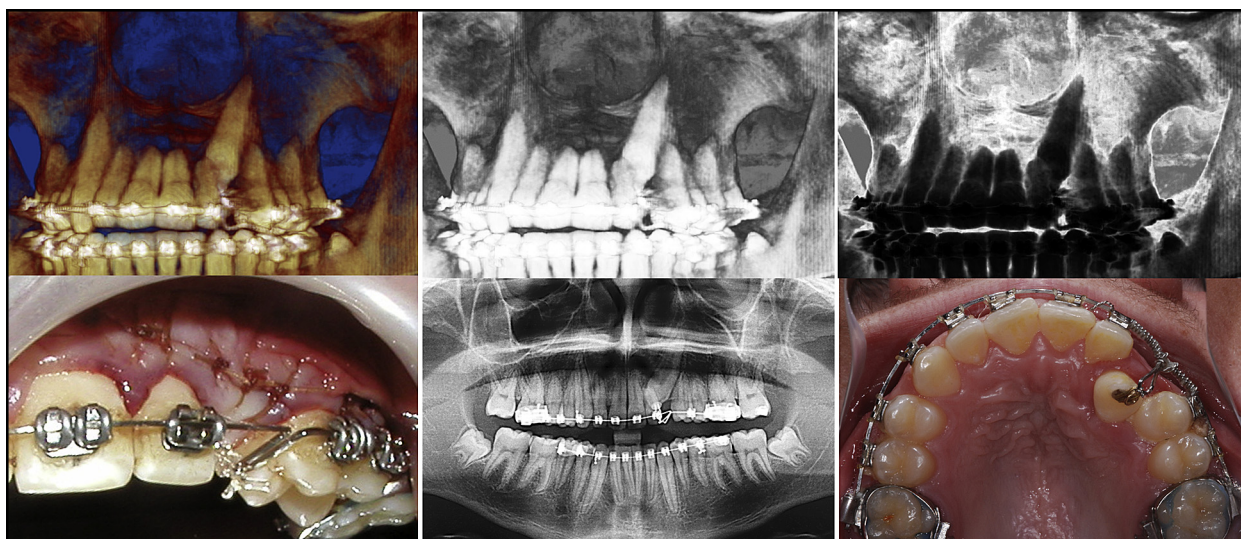
Patient 1, a 14-year-old white boy, presented for treatment at the Saint Louis University in St Louis, Mo. His medical history showed that he had type 1 diabetes, which was considered during treatment planning. The patient had a Class I malocclusion with significant crowding of the maxillary arch and an impacted maxillary left canine (Fig 1). After examining all records, it was decided to try to treat this patient without extractions. The patient had much growth left, and his dentition could very well develop into a Class III pattern. The treatment protocol included gaining space for the impacted canine, surgical exposure, and bonding of an attachment to bring the tooth into occlusion. The space between the lateral incisor and the first premolar was opened orthodontically. The closed-eruption surgical exposure technique of the canine was used, and traction was initiated (Fig 2).<sup>15</sup>

After 3 months, a bite opening on the left side was noted, with no movement of the canine. These signs suggested ankylosis. The patient's mother had an

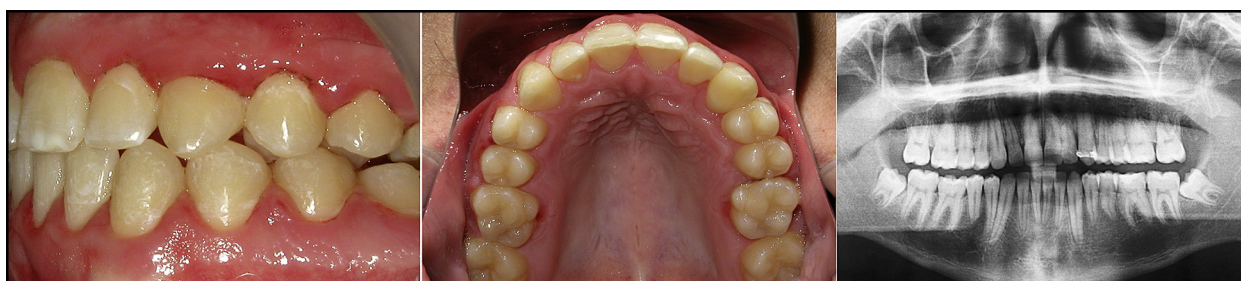
ankylosed canine, which had been extracted. The apicotomy procedure was explained to the patient and his family, and the decision was made to proceed with it. The surgery was done, and the canine traction was started after 1 week. A ballista loop was used initially. Six weeks later, the canine was erupting, and the traction was continued. After 10 weeks, the canine had been totally erupted, and its rotation and alignment in the arch had begun. The case was completed and the tooth was tested vital; after removal of the fixed appliance, recontouring of the gingiva was suggested for better esthetics. The final intercuspation and the torque of the impacted canine could have been better (Fig 3), but because the treatment had lasted too long and the patient's general health condition had worsened with his diabetes, the appliances were removed.

Patient 2 is a 22-year-old black man. He presented for treatment at Saint Louis University in St Louis, Mo. The records showed a Class I malocclusion with severe crowding. All teeth were present except the maxillary right canine. The maxillary right deciduous canine was still present (Fig 4). The impacted maxillary right canine was palatally positioned in relation to its deciduous predecessor. The treatment plan called for extraction of the maxillary and mandibular first premolars; they were extracted along with the maxillary right deciduous canine. Treatment progressed with the expectation that the impacted canine would erupt by itself. It did not, so the tooth was exposed, and traction was applied to bring it into alignment. Unfortunately, the canine did not move. The patient at this time already had the 4 premolars extracted, and the possibility of ankylosis of the maxillary right canine was evident (Fig 5).

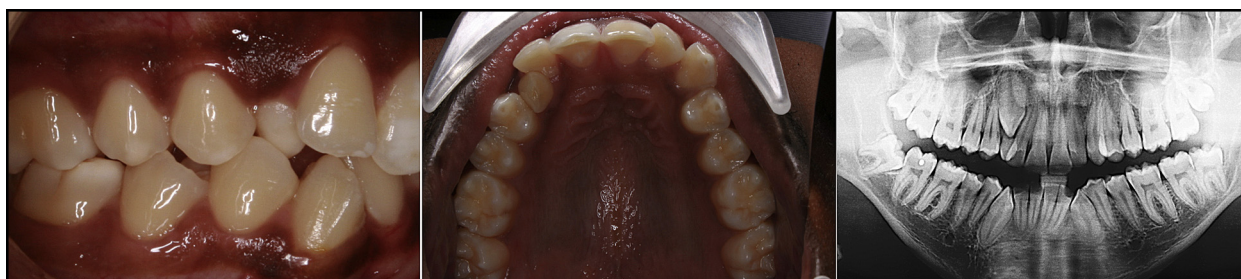Apicotomy was presented as an option to try to bring the tooth into the dental arch. The radiography showed the apex of the canine in the region of inverted Y of Ennis. The apicotomy was performed, and the canine responded well (Fig 5). The canine was initially moved with power thread and then a multiloop archwire; progressively, the tooth was brought into occlusion in a short time (Fig 6). Tooth vitality tested positive (Fig 7).



**Fig 2.** The maxillary left canine of patient 1 was positioned adjacent to the cortices of the nasal cavity and the maxillary sinus. An apicotomy was performed and traction applied to the canine with a ballista loop.



**Fig 3.** Final records of patient 1 show the canine in place. Periodontal esthetic laser procedure was recommended.

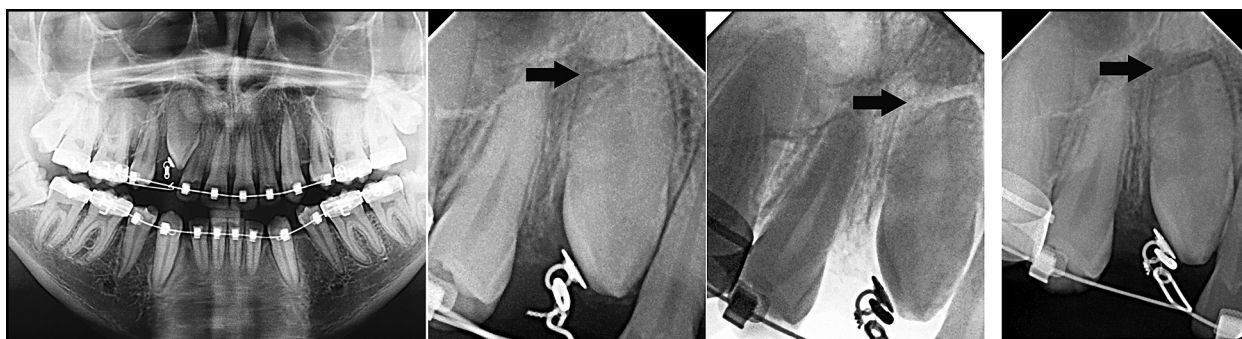


**Fig 4.** Patient 2 had a Class I malocclusion with an impacted maxillary right canine.

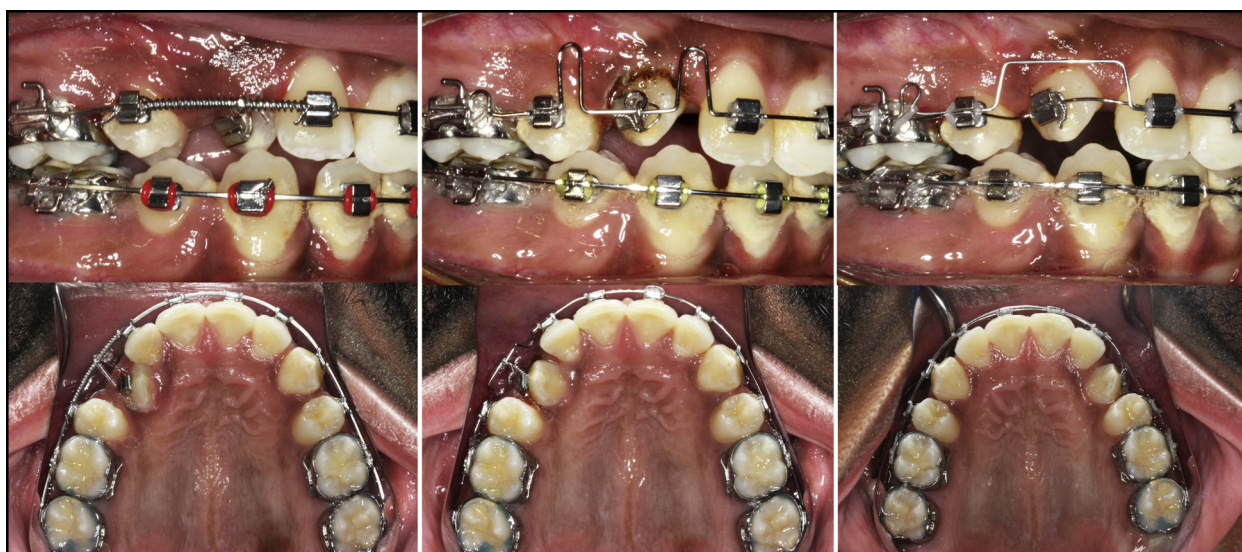
Patient 3 is a 17-year-old white girl with a severe Class III malocclusion (**Fig 8**). She presented for treatment at the University of Saint Louis in St Louis, Mo. After all records were taken and studied, a treatment plan with a surgical intervention was presented and accepted by the patient and her family. In addition to

the skeletal problem she had an impacted maxillary right canine labially positioned with dilaceration in the apical region (**Fig 9**). She needed to be orthodontically prepared for the orthognathic surgery, and extractions had to be performed. Because of the complexity and the crowding, the treatment plan called for maxillary and mandibular





**Fig 5.** All 4 of patient 2's first premolars were extracted, but the canine did not respond to traction. Apicotomy was performed. The apex was fractured and left in place (*arrows*).



**Fig 6.** Patient 2's canine was initially moved with power thread and progressively brought into occlusion.

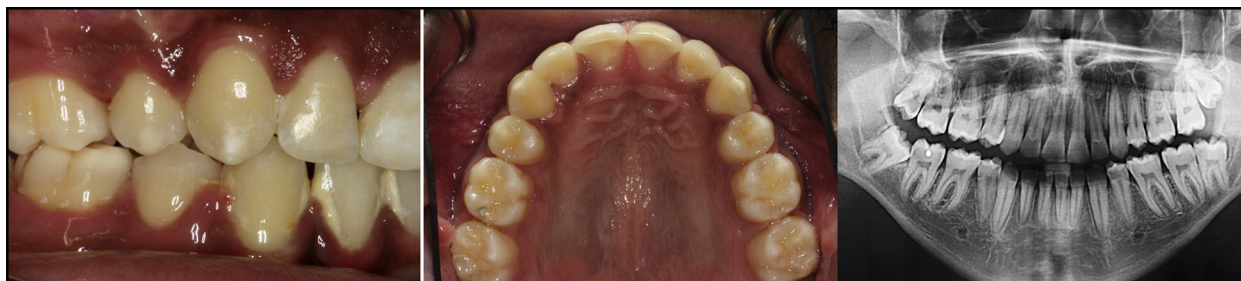extractions. In the maxillary right segment, 3 options were contemplated: extraction of the maxillary right first premolar, extraction of the maxillary right canine, or extraction of the maxillary right lateral incisor. The decision was to extract the lateral incisor and plan for canine substitution. In the left segment, the first premolar would be extracted. The maxillary right canine would need to be moved properly to make the plan possible. With caution, a decision was made to expose and retrieve the impacted canine before extracting the lateral incisor. After maxillary expansion and an excisional uncovering apically positioned flap technique, the canine initially showed some movement, but it stopped, and ankylosis was suspected.<sup>16</sup>

The lateral incisor was then moved palatally to allow more space for the canine. The cone-beam computed tomography image confirmed the position of the

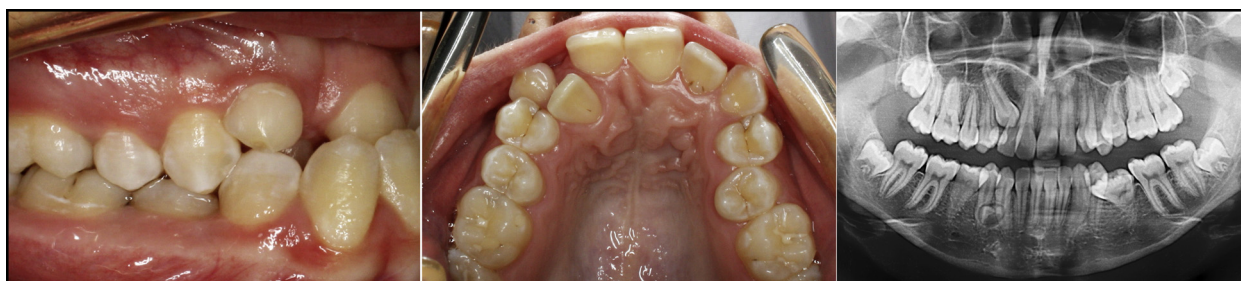canine apex close to the inverted Y of Ennis, and a dilaceration of the root apex was also noted (*Fig 10*). Thus, an apicotomy was recommended and performed successfully (*Fig 11*). After 1 month, the canine had been leveled and proved vital with electric pulp testing. The lateral incisor was extracted to continue the leveling and alignment procedures. Extractions of the malformed mandibular second premolars were also requested, and space closure is in its final stages. A negative overjet has been maintained in preparation for surgery.

## DISCUSSION

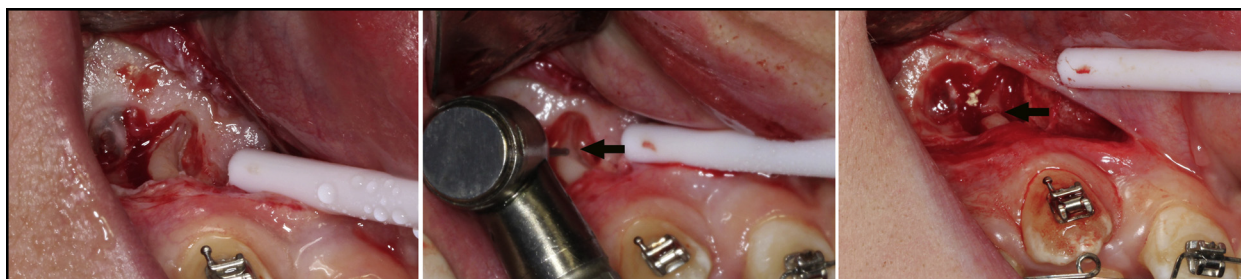
The purpose of this article is to present and describe the technique of apicotomy proposed by Puricelli<sup>13</sup> in 1987 as a viable option for dilacerated or ankylosed



**Fig 7.** The final records of patient 2 show the canine in place with good occlusion.



**Fig 8.** Patient 3 had a Class III malocclusion with an impacted maxillary right canine with a dilacerated apex.



**Fig 9.** Apicotomy procedure (arrows) for patient 3.

maxillary canines. The surgical procedure involves the separation and isolation of the apical region of the tooth root believed to be the site of ankylosis due to its proximity to the adjacent cortical bone.

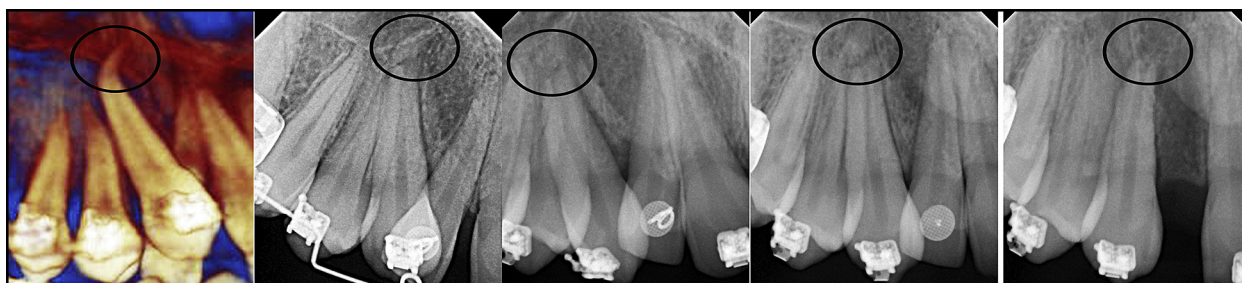Traditionally, once a tooth becomes ankylosed, surgical luxation has been the treatment of choice.<sup>8,17</sup> After surgical luxation, immediate orthodontic traction is performed.<sup>17</sup> If the tooth does not move during the next 6 months, the procedure is repeated; if it fails again, extraction of the ankylosed tooth is the treatment of choice.<sup>18</sup> Orthodontic light forces should be immediately applied after luxation to prevent reankylosis, but even with immediate traction, ankylosis often occurs again.<sup>19</sup>

With contemporary imaging techniques (cone-beam computed tomography), a better diagnosis of the area

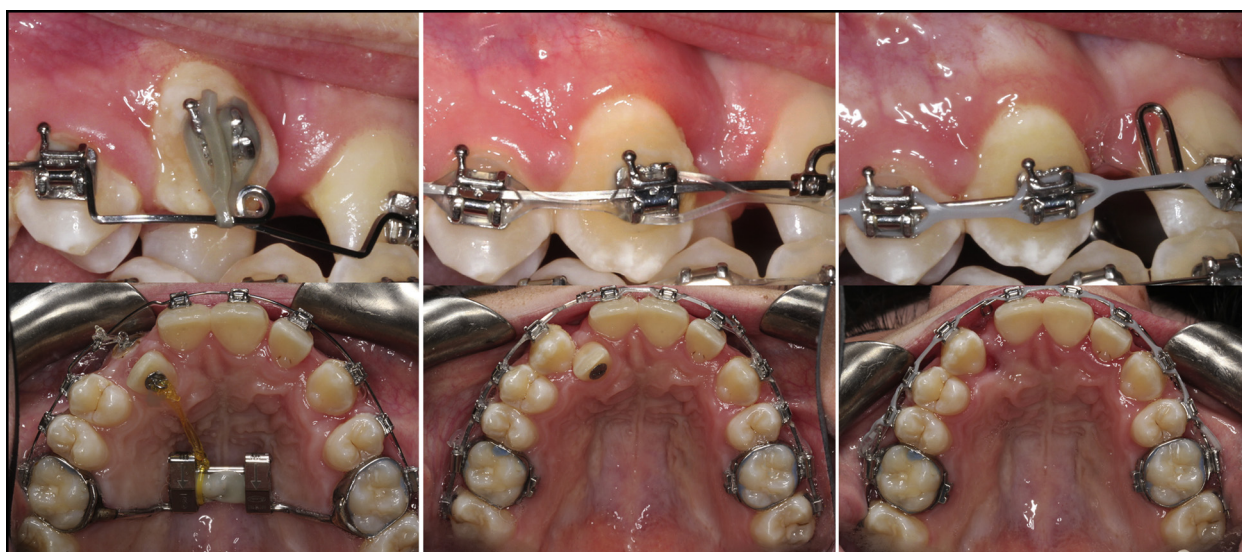
of ankylosis can be made.<sup>20</sup> These images were widely used for all patients here described. When properly indicated, as demonstrated in the 3 cases presented, it is reasonable to consider the apicotomy surgical procedure as a viable therapeutic option following the failure of other maxillary canine traction mechanics.<sup>14</sup>

Kokich<sup>21</sup> extensively reviewed the surgical and orthodontic management of impacted maxillary canines and stated that if not instructed properly, the surgeon could select an inappropriate technique, leaving the orthodontist with the difficult if not sometimes lengthy and challenging task of erupting the impacted tooth into the dental arch. On the other hand, if the correct technique is chosen, the eruption process can be simplified, resulting in a predictably stable and esthetic result.





**Fig 10.** The periapical radiographs of patient 3 show the line of separation of the dilacerated portion of the apex (circles).



**Fig 11.** Patient 3's lateral incisor was moved palatally to allow easier canine traction. After the eruption of the canine following the apicotomy surgical procedure, the lateral incisor was extracted.

In general, patients with impacted maxillary canines are perceived to be more difficult and time-consuming to treat than the average orthodontic patient.<sup>9</sup> Apicotomy has been successfully used during the past 25 years for conservative intervention in patients with suspected ankylosis of impacted maxillary canines, canines with dilacerations, or apical ankylosis, but it is contraindicated for young patients with incomplete rhizogenesis or for teeth with total root ankylosis.<sup>14</sup>

The incidence of ankylosed maxillary canines is low, but when conservative techniques for inducing spontaneous eruption and orthodontic traction fail, a number of unpleasant problems can happen for patients and orthodontists alike.<sup>22</sup> Although the mechanical management of impacted teeth is a routine task for most orthodontists, certain impactions can be frustrating.<sup>21</sup>

In the clinical cases presented here, the treatment plan was driven by the maintenance of the canines

instead of extraction and rehabilitation with a single-tooth implant-supported prosthesis, or closing the space by moving the posterior teeth forward. Additionally, the patients' cooperation and the parents' understanding allowed achieving esthetic and functional results.

## CONCLUSIONS

The apicotomy surgical technique can be an effective option as an adjunctive treatment for ankylosed or dilacerated maxillary canines after the failure of conservative orthodontics biomechanics.

## REFERENCES

1. Suri S, Utreja A, Rattan V. Orthodontic treatment of bilaterally impacted maxillary canines in an adult. *Am J Orthod Dentofacial Orthop* 2002;122:429-37.

2. Bass TB. Observations on the misplaced upper canine tooth. *Dent Pract Dent Rec* 1967;18:25-33.
3. Bjerklin K, Bondemark L. Management of ectopic maxillary canines: variations among orthodontists. *Angle Orthod* 2008;78:852-9.
4. Becker A, Smith P, Behar R. The incidence of anomalous maxillary lateral incisors in relation to palatally displaced cuspids. *Angle Orthod* 1981;51:24-9.
5. Lewis PD. Preorthodontic surgery in the treatment of impacted canines. *Am J Orthod* 1971;60:382-97.
6. Kuroi J. Impacted and ankylosed teeth: why, when, and how to intervene. *Am J Orthod Dentofacial Orthop* 2006;129(Suppl):S86-90.
7. Sapir S, Kalter A, Sapir MR. Decoronation of an ankylosed permanent incisor: alveolar ridge preservation and rehabilitation by an implant supported porcelain crown. *Dent Traumatol* 2009;25:346-9.
8. Takahashi T, Takagi T, Moriyama K. Orthodontic treatment of a traumatically intruded tooth with ankylosis by traction after surgical luxation. *Am J Orthod Dentofacial Orthop* 2005;127:233-41.
9. Sajjani AK, King NM. Retrospective audit of management techniques for treating impacted maxillary canines in children and adolescents over a 27-year period. *J Oral Maxillofac Surg* 2011;69:2494-9.
10. Becker A, Chaushu S. Success rate and duration of orthodontic treatment for adult patients with palatally impacted maxillary canines. *Am J Orthod Dentofacial Orthop* 2003;124:509-14.
11. Iramaneerat S, Cunningham SJ, Horrocks EN. The effect of two alternative methods of canine exposure upon subsequent duration of orthodontic treatment. *International J Paediatr Dent* 1998;8:123-9.
12. Stewart JA, Heo G, Glover KE, Williamson PC, Lam EW, Major PW. Factors that relate to treatment duration for patients with palatally impacted maxillary canines. *Am J Orthod Dentofacial Orthop* 2001;119:216-25.
13. Puricelli E. Treatment of retained canines by apicotomy. *RGD* 1987;35:326-30.
14. Puricelli E. Apicotomy: a root apical fracture for surgical treatment of impacted upper canines. *Head Face Med* 2007;3:33.
15. Vermette ME, Kokich VG, Kennedy DB. Uncovering labially impacted teeth: apically positioned flap and closed-eruption techniques. *Angle Orthod* 1995;65:23-32.
16. Vanarsdall RL, Corn H. Soft-tissue management of labially positioned unerupted teeth. *Am J Orthod* 1977;72:53-64.
17. Pithon MM, Bernardes LA. Treatment of ankylosis of the mandibular first molar with orthodontic traction immediately after surgical luxation. *Am J Orthod Dentofacial Orthop* 2011;140:396-403.
18. Biederman WR. Etiology and treatment of tooth ankylosis. *Am J Orthod* 1962;48:670-84.
19. Turley PK, Crawford LB, Carrington KW. Traumatically intruded teeth. *Angle Orthod* 1987;57:234-44.
20. Haney E, Gansky SA, Lee JS, Johnson E, Maki K, Miller AJ, et al. Comparative analysis of traditional radiographs and cone-beam computed tomography volumetric images in the diagnosis and treatment planning of maxillary impacted canines. *Am J Orthod Dentofacial Orthop* 2010;137:590-7.
21. Kokich VG. Surgical and orthodontic management of impacted maxillary canines. *Am J Orthod Dentofacial Orthop* 2004;126:278-83.
22. Kokich VG, Mathews DA. Impacted teeth: surgical and orthodontic considerations. In: McNamara JA Jr, editor. *Orthodontics and dentofacial orthopedics*. Ann Arbor, Mich: Needham Press; 2001.